

SUCCESSFUL SIMULTANEOUS CLEARANCE OF BILATERAL STAGHORN STONES WITH FLEXIBLE URETERO-RENSCOPIC LASERTRIPSY

Ahmed Kodera, Tara Burnhope & Vincent Koo

Department of Urology, Alexandra Hospital, Worcestershire Acute Hospitals NHS Trust, United Kingdom

Correspondence author: a.kodera@nhs.net

Abstract

A 50-year-old tetraplegic gentleman was referred with visible haematuria and recurrent urinary tract infections (UTI) presenting as behavioural difficulty. His past medical history includes diffuse brain injury following a motorbike accident, hypertension, BMI 41, performance status 4, and needing a hoist for transfer. CT showed bilateral staghorn complete calculi measuring the maximum length of 3 cm (left) and 4.2 cm (right) with 600 HU. Following best interest meetings, the patient communicated his unwillingness to proceed with PCNL or open surgery due to risks and opted for FURS. His bilateral staghorn stone was completely cleared simultaneously at his primary procedure after a total operative time of 190 min. He had no postoperative complications and was discharged with bilateral stents in situ. He had a second-look FURS 4 weeks later but only required washout of minimal dust and removal of bilateral ureteric stents. His stone analysis confirmed struvite stone. His haematuria, recurrent UTIs, and behavioural issues were resolved. His 6 months postoperative CTKUB showed a dust-free status. This report discusses the challenges of simultaneous bilateral staghorn clearance using FURS.

Keywords: *flexible ureterorenoscopy; lasertripsy; retrograde intrarenal surgery; Staghorn stone; PCNL*

INTRODUCTION

Flexible ureterorenoscopic (FURS) lasertripsy is a recognised treatment for kidney stones. In addition, FURS can be used for staghorn stones where PCNL is contraindicated. We have previously documented the first successful case of a complete staghorn treated with FURS.¹ Subsequently, further series of staghorn stone treatment with FURS^{2,3} yielded good outcome results. This case of simultaneous clearance of bilateral complete staghorn stones by primary FURS lasertripsy alone is presented, and the technique and challenges are discussed.

CASE

A 50-year-old tetraplegic gentleman was referred to the Haematuria clinic with visible

haematuria and recurrent urinary tract infections (UTI) presenting as behavioural difficulty. His past medical history includes diffuse brain injury following a motorbike accident, hypertension, BMI 41, and performance status 4 needing a hoist for transfer. His flexible cystoscopy was normal and CTKUB shown in Figure 1 and 3-dimensional reconstructed image in Figure 2 showed bilateral staghorn calculi measuring a maximum length of 3 cm (left) and 4.2 cm (right) measuring an average of 600 HU.

He had no next of kin and hence his social worker and case manager and Independent Mental Capacity Advocate (IMCA) accompanied him to the clinic to counsel his treatment options. He was counselled for standard PCNL and the alternative multiple FURS treatment. In the subsequent

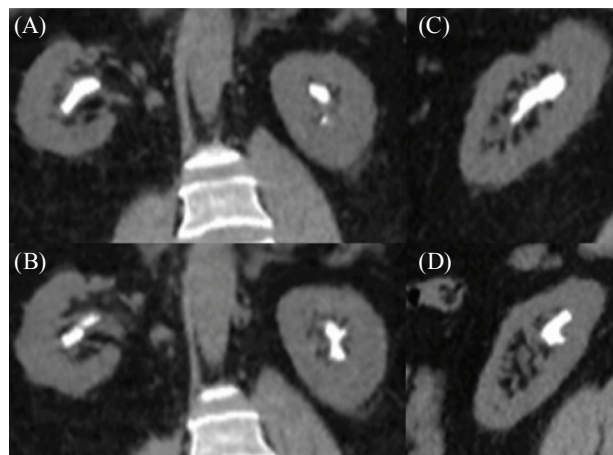


FIGURE 1 CTKUB scan coronal images of bilateral staghorn stone (A and B). Sagittal image of right staghorn (C) and left staghorn (D).

follow-up best interest meeting, in consensus with his carers, IMCA, and general practitioner (GP), he opted to undergo FURS. His preoperative mid-stream urine sample showed mixed growth UTI. He was put on prophylactic low-dose Trimethoprim.

At GA induction, he received 160 mg IV Gentamicin and 1.2 g IV Coamoxiclav. He was put in lithotomy position with Bair Hugger™ (3M, USA) normothermia system and Flowtrons® (Arjo Hunleight, Sweden) intermittent pneumatic compression device. Rigid cystoscopy revealed a dense mid-penile urethral stricture which was dilated successfully. 7F Karl-Storz® Semi-rigid Ureteroscopy did not show any ureteric pathology. Boston Scientific Navigator™ 46 cm 11/13F ureteric access sheath was inserted above the pelviureteric junction. Boston Scientific Lithovue flexible uretero-renaloscopy was performed. Lasertripsy was done using 200 µm Boston Scientific Flexiva™ Tractip laser fibre, with 1.0 J × 20 Hz from Versapulse® Powersuite™ (Lumenis, Israel). Pressurised saline irrigation (150 mm Hg) was used on First FURS, gravity only (nonpressured) for the second FURS.

The left staghorn took 60 min to clear. Its upper pole branch configuration and acute infundibular angulation required extreme torque and deflection of the scope, which resulted in scope failure at

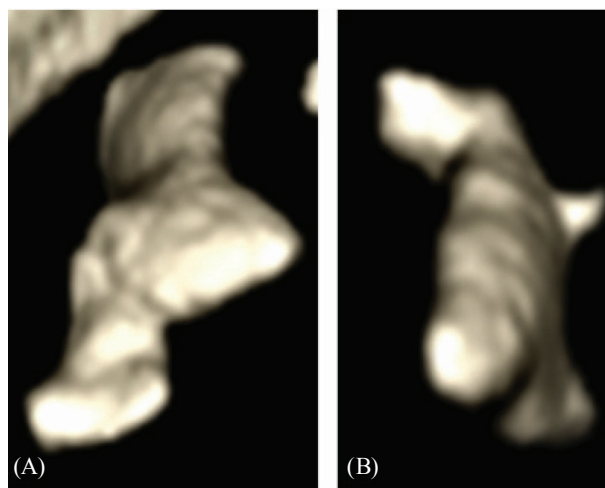


FIGURE 2 Reconstructed 3-Dimensional CT images of Right (A) and (B) Left staghorn.

completion of staghorn clearance. A new Lithovue scope was needed to clear the right staghorn. The right side took 130 min to clear and the procedure concluded with bilateral 24 cm 6F ureteric stent and a silicone urethral catheter. He made an uneventful recovery in the ward, without the need for high-dependency care. He did not have any postoperative complications and was fit to be discharged home the next day with bilateral stents in-situ and urethral catheter. Due to social circumstances he stayed at the hospital 2 further days after surgery.

He returned after 4 weeks for another GA procedure to remove bilateral stents and for a second look at FURS. There were only minimal dust seen in bilateral kidneys and these were washed out; both stents were removed and he had a trial without catheter. He made good recovery, without any complications and was medically fit for discharge, which happened 1 day later again due to social circumstances. His 6 months follow-up CTKUB in Figure 3 did not show any residual stones or dust.

DISCUSSION

Traditionally, PCNL has been the main stay of treatment for staghorn stones. The reason behind this is that most studies have shown higher SFR

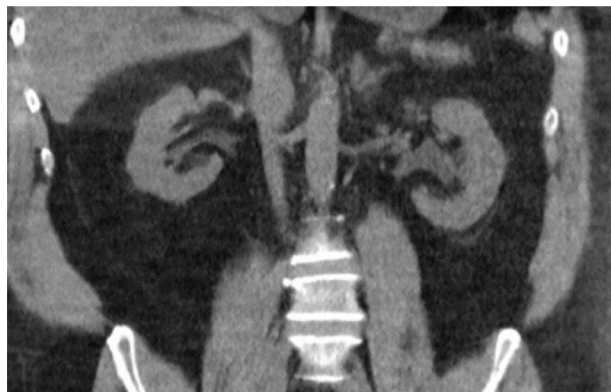

FIGURE 3 Six months postop CTKUB images showing dust-free status.

with PCNL (88–91%) compared to Ureteroscopy monotherapy (59–75%), respectively. In a systematic review, only five studies were identified (mostly case series) regarding the role of Ureteroscopy in the treatment of Staghorn stones.⁵ The main advantages of URS monotherapy over PCNL were shorter length of stay, less or no complications as well as the ability to offer modality in borderline fit patients. The main limiting factor of Ureteroscopy in the treatment of staghorn stones has been the inferior stone clearance capacity of URS as compared to PCNL.⁶ This obstacle has been overcome in some series of URS monotherapy by active washout of stone dust/small fragments through ureteric access sheath as previously described.¹

In our case, counselling and consenting for the procedure was challenging both from the patient's perspective, as well as carers and relevant stakeholders. Communication was challenging and required patience from all parties to ensure that the correct message has been relayed. The patient had no next of kin, and required an IMCA to help with the consenting process. It needed two separate best interest meetings with adequate time for all parties to understand the treatment options and associated risks and also his GP support letter to confirm that the appropriate choice of treatment has been made. From the patient's perspective, he was concerned about the small but significant risk of viscus perforation/kidney and lung damage from bilateral PCNL.

He also had personally witnessed GA complication from his father's surgery and hence opted for the minimally invasive FURS. In addition, he was a Star Wars fan and relished the idea of laser surgery (he was extremely delighted when the surgeon (VK) came dressed in a Jedi cloak to confirm his consent).

From the Endourologist's perspective, there is great demand for both mental focus and physical stamina, especially when possibly considering bilateral FURS procedure. The potential bilateral procedure was estimated to last for at least 4 h or more. The author (VK) has been regularly performing FURS for staghorn and complex stones, and the longest single session of FURS took about 3 h and 30 min.

All equipment was double-checked to be working in good order, and the theatre staff and anaesthetist were briefed 1 week prior. Plans for replacement staff at different time points were agreed upon, but it was not needed as the procedure concluded earlier than expected. Replacement scopes, additional laser fibres, and a standby second laser machine were available for use on the day. Adequate theatre time and anaesthetic recovery time were reserved on the theatre list. High Dependency Unit bed was pre-booked, but was not needed.

The management of bilateral staghorn is challenging irrespective of PCNL or FURS treatment. Simultaneous bilateral PCNL for staghorn treatment previously reported stone clearance rate of 71%, average operative time of 244 min, 3.6 days average length of stay, 6% blood transfusion rate, with 10% of Clavien-Dindo 1 complications and 6% of Clavien-Dindo 2 complications.⁴ If PCNL was chosen, it would be unlikely that bilateral procedure would have been done in a single setting, given his comorbidities and body habitus. The original intention was to clear each staghorn at separate GA settings, but following further counselling with all stakeholders and the patient, it was decided that if the FURS went well, and provided that it was deemed clinically safe to proceed, then bilateral procedure should be attempted due to practicalities and health concerns.

The clearance of the smaller left staghorn went on well in a relatively short time, and he remained

stable. A discussion with the consultant anaesthetist took place; because the patient had remained anaesthetically well with no signs of sepsis, the contralateral staghorn clearance was attempted. Like all complex FURS stone treatments, if at any point there were any concerns or surgical difficulties, the procedure would conclude prematurely with stenting and the patient would be asked to come back for another session. Similar to all staghorn FURS treatments, it can be challenging due to the difficult access to the “curve” stone profile of the staghorn, which is almost always adherent to the calyceal mucosa. Releasing the stone by lasering often causes some bleeding and together with the dust burden adds further challenge to the procedure. Pressured saline (150 mmHg) was helpful in aiding clearer vision. Given time, this staghorn was eventually cleared successfully.

It is the author’s experience (VK) that a GA second-look FURS is useful to washout or basket out any remnant fragments to ensure dust-free status. Furthermore, the post-stenting does facilitate quicker relook FURS. In this case, only minimal dust was found, washout was done, and both stents were removed. Arguably removal of bilateral stents under LA would have been challenging for this patient. Thankfully, he did not have any stent symptoms or any complication. The resultant dust-free status was proven on CTKUB 6 months later and the resolution of his presenting symptoms were the best outcome for this patient.

CONCLUSION

In the context of staghorn calculi treatment, simultaneous clearance of bilateral staghorn by FURS was successfully and safely carried out.

Conflicts of interest

None declared.

REFERENCES

1. Koo V. Single-Stage Flexible Uretero-Renoscopic Lasertripsy Clearance of Staghorn Stone. *ARC J Urol*. 2017; 2(3):12–14.
2. Koo V, Ahmed M, Deshpande A, Kodera A. Preliminary outcome comparison of Flexible Uretero-renaloscopic lasertripsy versus PCNL in the treatment of staghorn calculi. *J Endol Endo*. 2020; 3(2):e31–e36. <https://doi.org/10.22374/jeleu.v3i2.89>
3. Ahmed M and Koo V. Outcomes of Flexible Ureterorenoscopic lasertripsy in the treatment of staghorn stones. *J Endol Endo*. 2019; 2(SP1):e2.
4. Wang CJ, Chang CH, Huang SW. Simultaneous bilateral tubeless percutaneous nephrolithotomy of staghorn stones: a prospective randomized controlled study. *Urol Res*. 2011;39(4):289–94.
5. Etienne XK, Vincent DC, Steeve D, Olivier T. The role of ureteroscopy for treatment of staghorn calculi: A systematic review: *Asian. J Urol*. 2020;7(2):110–115.
6. Etienne XK, Vincent DC, Olivier T. Next-Generation Fiberoptic and Digital Ureteroscopes: *Urol Clin North Am*. 2019;46(2):147–63.